

Case Report

Iatrogenic Pneumothorax Caused by Thoracic Puncture Secondary to Anti-aging Medicine

Yamile Martinez-Rodriguez, Zobeida Rodriguez-Diaz, Fernanda Tellez-Quijada, Brenda Sanchez-Melo and Ivette Buendia-Roldan*

National Institute of Respiratory Diseases "Ismael Cosío Villegas", CP 14080, Mexico City, Mexico

Abstract

Introduction: Pneumothorax is defined as air in the pleural cavity, the iatrogenic cause happens after invasive procedures as thoracic needle aspiration, central line placement, pacemaker placement, etc. Nevertheless, it is possible to be found in non-medical procedures, such as alternative medicine, more specifically acupuncture. There are medications used against aging that FDA has warned to be used only in its first objective, an example is procaine hydrochloride.

Case: A 63 y/o female, Mexico City resident, with anxiety, came to a follow-up appointment for an aging cohort, where CT, PFT, and laboratories are made for pulmonary healthy subjects to investigate normal lung aging and how other environmental factors can affect the lungs; at physical examination, we did not find any pleuropulmonary syndrome, but in the CT a left iatrogenic pneumothorax was found; we re-asked for antecedents and she described that 15 days before the date she had 2 punctures in the middle clavicular line to apply procaine hydrochloride as an anti-aging treatment.

Discussion: There is diverse evidence of adverse effects associated with acupuncture, and even if pneumothorax has a small percentage of incidence, in some cases it can be severe and can even cause fatalities.

Conclusion: The pneumothorax in this case was iatrogenic due to the thoracic puncture for an anti-aging treatment, with a total resolution with conservative treatment, however we as health professionals have the responsibility to inform our patients that initiatives of administration ways can cause important complications.

Introduction

Pneumothorax is defined as air in the pleural cavity, there are different types of pneumothorax: spontaneous and traumatic, which we can include iatrogenic; classically consist of a penetrating thoracic injury, and it usually occurs after invasive procedures, the most common cause is a central line placement, it also is related with thoracic needle aspiration, pacemaker placement, bronchoscopic lung biopsies, and pleural biopsy; however, it is possible to be found, in procedures, especially in the ones that consist in chest puncture, such as acupuncture [1-3].

The epidemiology of pneumothorax in Mexico is unknown, however using other countries as examples, men have more risk of having pneumothorax than women; besides

the adverse effects, increases if the subject has a medical history of thoracic surgery, chronic bronchitis, emphysema, tuberculosis, and pulmonary cancer [4].

There are different adverse effects caused by acupuncture, being the most severe pneumothorax, cardiac tamponade, and nervous injury; that is the reason why we have to be careful when needles puncture in body risk areas, in this case, the thorax, which can cause important organ damages and can be fatal if not treated [5].

Procaine hydrochloride, H3 (Gerovital ®), an inhibitor of monoamine oxidase, was initially used in patients with depression, however during the 70's decade, it was used, as a treatment against aging; during that time, there was no scientific evidence that demonstrated this effect, and FDA

More Information

***Address for correspondence:**

Dr. Ivette Buendia-Roldan, National Institute of Respiratory Diseases "Ismael Cosío Villegas", CP 14080, Mexico City, Mexico, Email: ivettebu@yahoo.com.mx

Submitted: July 12, 2023

Approved: July 26, 2023

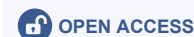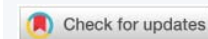Published: July 27, 2023

How to cite this article: Martinez-Rodriguez Y, Rodriguez-Diaz Z, Tellez-Quijada F, Sanchez Melo B, Buendia-Roldan I. Iatrogenic Pneumothorax Caused by Thoracic Puncture Secondary to Anti-aging Medicine. Arch Case Rep. 2023; 7: 032-034.

DOI: 10.29328/journal.acr.1001073

Copyright license: © 2023 Martinez-Rodriguez Y, et al. This is an open access article distributed under the Creative Commons Attribution License, which permits unrestricted use, distribution, and reproduction in any medium, provided the original work is properly cited.

Keywords: Iatrogenic pneumothorax; Procaine hydrochloride; Aging



in 1982 decided to make an alert, with the purpose to only be used for its first indication, patients with depression; and being intramuscular its administration way [6].

Some studies made by different authors such as Cohen, Zwerling, and Zung, in the 1970s showed an improvement in patients with depression in treatment with procaine hydrochloride, all of them using an intramuscular administration [7-9].

According to Ostfeld, the literature on this drug for the elderly did not have the quality of trials of new treatments, therefore it is not secure to use this drug in this population [10].

Case report

Female 63 years old, Mexico City resident, who has lived the majority of her life in Mexico City, with a history of anxiety that started 5 years ago, she denies any history of other chronic disease, traumas, hospitalizations, or trips; she comes to the INER- Instituto Nacional de Enfermedades Respiratorias "Ismael Cosío Villegas" (National Institute of Respiratory Diseases) to the aging cohort; which pulmonary healthy people older than 60 years old are studied; respiratory function test, 6-minute walk, Computed Tomography (CT) and laboratories are made, to know the normal lung aging, and how other factors can affect the lungs.

At the physical examination, a pleuropulmonary syndrome was not found. Vital signs: SpO₂ 94% FiO₂ 21% respiratory frequency 18, cardiac frequency 75, arterial pressure 96/64, temperature 36.5.

CT was reviewed and found a left iatrogenic pneumothorax; at the interrogation, she referred that 15 days prior to the INER appointment, procaine hydrochloride was applied as an anti-aging treatment, with a thoracic puncture in the middle clavicular line 2 times.

Three months later, thoracic radiography was made with the objective of following the pneumothorax, in which we found a total resolution of pneumothorax Figure 1.

Discussion

Iatrogenic pneumothorax can be caused by health workers, but it can also be found in procedures not made in the hospital, such as alternative medicine, like acupuncture,

and it can affect the health of healthy subjects in the short, medium, and long term.

The treatment of pneumothorax depends on its size and symptoms; if it is small (<4 cm or < 20%) and with no dyspnea or pleuritic chest pain, like in this case, conservative treatment can be used as a management strategy, and weekly x-ray checks are sufficient [2,3].

There have been reported mild complaints of nausea and headache in intramuscular administration, however, it has never been reported pneumothorax with the use of Gerovital®, because its administration way is intramuscular; not thoracic. Therefore, this case report will be compared with acupuncture cases, with the consideration that this type of application is made with a needle gauge bigger than the ones used in acupuncture [11].

Many reports have demonstrated adverse effects associated with acupuncture if not done correctly; one of them is a study made in Germany; in which 8.6% of the population evaluated (19,726 out of 229,230 subjects) presented adverse effects, going from hematoma (58%) to pneumothorax (2 cases) or nervous injuries (31 cases) [12].

It was also observed in a study made in Taiwan that an incidence of adverse effects is 0.87 for every 1.000.000 procedures in general, but it increases to 1.75 for every 1.000.000 in procedures in risk anatomic areas, such as thorax, especially in middle scapular or middle clavicular areas [4,13].

According to Cohen et al. the administration dose is 100-200 mg 3 times weekly intramuscular for 4 weeks, however in this case was not used administration indicated, and was made as thoracic puncture, which incremented the risk of puncturing the lung, and therefore having pneumothorax [7].

In recent years, there are few studies made of this drug, one of them in 2009, to treat dementia and cognitive impairment, in which the data did not support the use to treat or prevent either of them; also in the year 2020, an in vitro study was made for radioprotective effect, however, there was not a difference between young and aged individuals; there are no recent clinical trials for its anti-aging use; this supports that this drug should not be used in any other pathologies but depression [14,15].

Conclusion

Pneumothorax, in this case, was iatrogenic and caused by a non-indicated way of administration, thoracic puncture, for anti-aging, it had a total resolution with conservative treatment; despite this, an initiative of new administration ways can result in an important complication, the presentation of this case has the finality to inform that even if alternative medicine can be helpful, it is important that patients are sensitized to the complications that can outcome if it is not used as an indicated administration way.

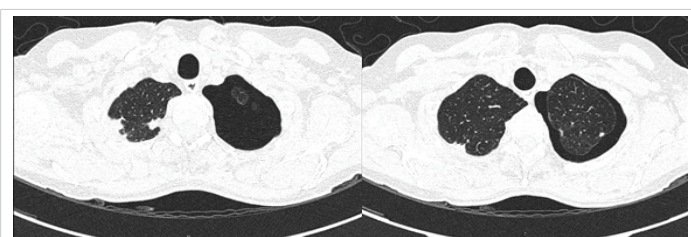


Figure 1: High-resolution computed tomography shows left pneumothorax in the superior lobe both images taken from the aging appointment.



Informed consent statement

This article was made from the protocol approved by the Ethics Committee of INER, C39-14. Consent for publication was obtained from the patient.

References

- Ojeda Rodriguez JA, Hipskind JE. Iatrogenic Pneumothorax. 2022 Aug 17. In: StatPearls [Internet]. Treasure Island (FL): StatPearls Publishing; 2023 Jan-. PMID: 30252313.
- DeMaio A, Semaan R. Management of Pneumothorax. *Clin Chest Med.* 2021 Dec;42(4):729-738. doi: 10.1016/j.ccm.2021.08.008. PMID: 34774178.
- Eggeling S. Pneumothorax [Pneumothorax]. *Zentralbl Chir.* 2021 Feb;146(1):126-144. German. doi:10.1055/a-1256-6008. Epub 2021 Feb 15. Erratum in: *Zentralbl Chir.* 2021 Feb;146(1):e8. PMID: 33588508.
- Lin SK, Liu JM, Hsu RJ, Chuang HC, Wang YX, Lin PH. Incidence of iatrogenic pneumothorax following acupuncture treatments in Taiwan. *Acupunct Med.* 2019 Dec;37(6):332-339. doi: 10.1136/acupmed-2018-011697. Epub 2019 Aug 21. PMID: 31433202.
- Zhang J, Shang H, Gao X, Ernst E. Acupuncture-related adverse events: a systematic review of the Chinese literature. *Bull World Health Organ.* 2010 Dec 1;88(12):915-921C. doi: 10.2471/BLT.10.076737. Epub 2010 Aug 27. PMID: 21124716; PMCID: PMC2995190.
- Perls T. The reappearance of procaine hydrochloride (Gerovital H3) for antiaging. *J Am Geriatr Soc.* 2013 Jun;61(6):1024-1025. doi: 10.1111/jgs.12278. PMID: 23772727.
- Cohen S, Ditman KS. Gerovital H3 in the treatment of the depressed aging patient. *Psychosomatics.* 1974;15(1):15-9. doi: 10.1016/S0033-3182(74)71288-9. PMID: 4606585.
- Zwerling I, Plutchik R, Hotz M, Kling R, Rubin L, Grossman J, Siegel B. Effects of a procaine preparation (Gerovital H3) in hospitalized geriatric patients: a double-blind study. *J Am Geriatr Soc.* 1975 Aug;23(8):355-9. doi: 10.1111/j.1532-5415.1975.tb00326.x. PMID: 1097490.
- Zung W, Gianturco D, Pfeiffer E, Wang H, Whanger A. Pharmacology of Depression in the Aged: Evaluation of Gerovital H3 as an Antidepressant Drug. *Psychosomatics.* 1974;15(3):127-131. doi:10.1016/S0033-3182(74)71260-9
- Ostfeld A, Smith CM, Stotsky BA. The systemic use of procaine in the treatment of the elderly: a review. *J Am Geriatr Soc.* 1977 Jan;25(1):1-19. doi: 10.1111/j.1532-5415.1977.tb00917.x. PMID: 12204.
- Perazzo F, Fonseca F, Souza G, Maistro E, Rodrigues M. Double-blind clinical study of a multivitamin and polymineral complex associated with panac ginseng extract (Gerovital®). *The Open Complementary Medicine Journal.* 2010; 2:100-104. <https://www.repositorio.ufop.br/handle/123456789/8905>.
- Witt CM, Pach D, Brinkhaus B, Wruck K, Tag B, Mank S, Willich SN. Safety of acupuncture: results of a prospective observational study with 229,230 patients and introduction of a medical information and consent form. *Forsch Komplementmed.* 2009 Apr;16(2):91-7. doi: 10.1159/000209315. Epub 2009 Apr 9. PMID: 19420954.
- Karavis MY, Argyra E, Segredos V, Yiallouroy A, Giokas G, Theodosopoulos T. Acupuncture-induced haemothorax: a rare iatrogenic complication of acupuncture. *Acupunct Med.* 2015 Jun;33(3):237-41. doi: 10.1136/acupmed-2014-010700. Epub 2015 Mar 19. Erratum in: *Acupunct Med.* 2016 Feb;34(1):71. PMID: 25791844; PMCID: PMC4483786.
- Szatmári S, Bereczki D. Procaine treatments for cognition and dementia. *Cochrane Database Syst Rev.* 2008 Oct 8;(4):CD005993. doi: 10.1002/14651858.CD005993.pub2. PMID: 18843698.
- Ungurianu A, Margina D, Borsa C, Ionescu C, von Scheven G, Oziol L, Faure P, Artur Y, Bürkle A, Gradinaru D, Moreno-Villanueva M. The Radioprotective Effect of Procaine and Procaine-Derived Product Gerovital H3 in Lymphocytes from Young and Aged Individuals. *Oxid Med Cell Longev.* 2020 Jun 24;2020:3580934. doi: 10.1155/2020/3580934. PMID: 32685092; PMCID: PMC7334788.