

Case Report

Delayed penile prosthesis implantation in the delayed presentation of ischemic priapism

IRZI Mohamed^{1*}, MHANNA Tarik², EL HOUMAIIDI Amine³, Mohammed Aynaou⁴, Mehdi Chennoufi⁵, OURAGHI Abdelghani⁶, ALAOUI MHAMMEDI Wassim⁷ and Ali Barki⁸

¹MD, Department of Urology, Mohammed IV University Medical Center, Mohammed The First University Oujda, Morocco

²MD, Department of Urology, Mohammed IV University Medical Center, Mohammed The First University Oujda, Morocco

³MD, Department of Urology, Mohammed IV University Medical Center, Mohammed The First University Oujda, Morocco

⁴MD, Department of Urology, Mohammed IV university Medical Center, Mohammed the first University Oujda, Morocco

⁵MD, Department of Urology, Mohammed IV university Medical Center, Mohammed the first University Oujda, Morocco

⁶MD, Department of Urology, Mohammed IV university Medical Center, Mohammed the first University Oujda, Morocco

⁷MD, Department of Urology, Mohammed IV university Medical Center, Mohammed the first University Oujda, Morocco

⁸MD, Head of Department of Urology, Mohammed IV University Medical Center, Mohammed The First University Oujda, Morocco

More Information

***Address for Correspondence:** IRZI Mohamed, MD, Department of Urology, Mohammed IV University Medical Center, Mohammed The First University Oujda, Morocco, Tel: 0623972021; Email: irziirzi1992@hotmail.com

Submitted: 20 December 2019

Approved: 05 February 2020

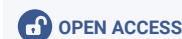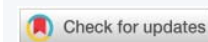
Published: 06 February 2020

How to cite this article: Mohamed I, Tarik M, Amine E, Aynaou M, Chennoufi M, et al. Delayed penile prosthesis implantation in the delayed presentation of ischemic priapism. Arch Case Rep. 2020; 4: 004-006.

DOI: dx.doi.org/10.29328/journal.acr.1001028

Copyright: © 2020 Mohamed I, et al. This is an open access article distributed under the Creative Commons Attribution License, which permits unrestricted use, distribution, and reproduction in any medium, provided the original work is properly cited.

Keywords: Priapism; Fibrosis; Malleable penile prosthesis



Abstract

Priapism is currently defined as a prolonged painful erection without sexual stimuli, if priapism persists > 36 hours, conservative treatment does not lead to detumescence.

The most common etiologies are: medications into corpora cavernosa, anti-psychotics, anti-hypertensives, hematological disorders (chronic myeloid leukemia).

The Penile prosthesis is the choice treatment for restoring the erectile function after the failure of the conservative treatment.

But the corporal fibrosis makes it very difficult, with high risk of complications [1].

Introduction

Ischemic Priapism (IP) is currently defined as a prolonged painful erection without sexual stimuli, the most common etiologies are: medications into corpora cavernosa, anti-psychotics, antihypertensive, hematological disorders (chronic myeloid leukemia).

If priapism persists > 36 hours, the management is difficult, irreversible damage was installed, and the detumescence after conservative treatment is rare.

The consequence of prolonged priapism is corpora cavernosa fibrosis with erectile dysfunction resistant to all medical treatments.

The only treatment to restore sexual function is the implantation of penile prosthesis, this is technically very difficult with high risk of complications and poor results.

Initial presentation

A 36 year-old Moroccan male with a history of chronic myeloid leukemia (CML), diagnosed at age 33. Presented during his hospitalization in internal medicine a persistent and painful erection of 5 days.

He was not in respiratory distress and denied other common symptoms of CML including fatigue, fever, chills, and shortness of breath, visual changes, or abdominal pain.

The patient was otherwise healthy and had no other pertinent medical or surgical history.

The physical examination revealed a fully erect interesting the corpora cavernosa, and penile pain exacerbated by palpation.

Proximal surgical shunt was performed, and the priapism relieved.

3 months later, the patient had erectile dysfunction and penile size reduction. We admitted the patient for penile malleable prosthesis implantation (PPI) as a strategy to restore erectile function.

Discussion

The mechanism of priapism during CML is venous obstruction due to hyper viscosity and leukocytosis.

The prolonged ischemic priapism (greater than 36 hours) is correlated a high rate of failure of conservative treatment (shunt).

In our case, the diagnosis was delayed after 5 days, a proximal shunt was performed and the priapism resolved. The evolution marked the appearance of an erectile dysfunction resistant to any treatment with shortening of the penis (Figure 1), this is related to the fibrosis of the corpora cavernosa.

The penile malleable prosthesis was the therapeutic choice for restoring the patient's sexual function.

Several studies in literature have shown the interest of the immediate implantation of the penile prosthesis. But there is no comparative study between early end delay implantation confirms the interest of the immediate implantation [2].

Res, et al., report that 80% of patients with RIP (refractory ischemic priapism) had a malleable penile prosthesis, 20% had an inflatable prosthesis. 50% of patients treated by inflatable prosthesis were complicated by penis deformation [3].

The interest of malleable penile prosthesis implantation is to avoid the shortening of the penis and used as a 'spacer' to prepare the penis for implantation of the penile prosthesis inflatable (Figure 3).

The interest of our case is delay the penile prosthesis a few weeks after the disappearance of the hematoma and edema that are incriminated in infectious complications. And prove the efficiency of delayed penile prosthesis.

The implantation penile malleable prosthesis after fibrosis installation is very difficult with high risk of complications [4,5].

Different techniques have been described in the literature for ease of IPP. We used drilling in fibrotic tissue as described by Wilson, et al. [5], (Figure 2).

The malleable penile prosthesis was sutured with the albugina to avoid the distale migration.

The most formidable complications are infection and distal cylinder migration [6]. We reported no infection and distal cylinder migration men at a mean follow-up period of 10 months.

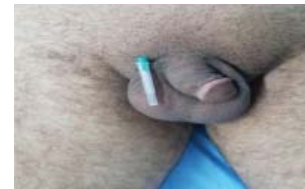

Figure 1: Post-priapism penile shortening.

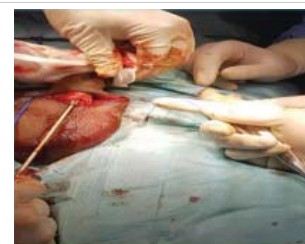

Figure 2: Drilling into the fibrous cavernous tissue.

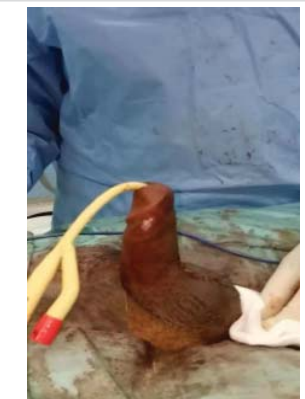

Figure 3: Malleable penile prosthesis implantation.

Conclusion

Ischemic priapism is a urological emergency. After conservative treatment of the priapism episode, Patients with medically refractory erectile dysfunction can be considered for penile implants, but it should be kept in mind that PPI in patients with corporal fibrosis is among the most challenging procedures.

References

1. Sun HH, Zhang JH, DeWitt-Foy M, Waldron M, Mukherjee S, et al. Montague: Urologic Management of Priapism Secondary to Chronic Myeloid Leukemia. *Urology*. 2019; 125: 24-28.
PubMed: <https://www.ncbi.nlm.nih.gov/pubmed/30471371>
2. Capece M, La Rocca R, Mirone V, Bivalacqua TJ, Castiglione F, et al. A Systematic Review on Ischemic Priapism and Immediate Implantation: Do We Need More Data? *Sex Med Rev*. 2019; 7: 530-534.
PubMed: <https://www.ncbi.nlm.nih.gov/pubmed/30898595>



3. Rees RW, Kalsi J, Minhas S, Peters J, Kell P, et al. The management of low-flow priapism with the immediate insertion of a penile prosthesis. *BJU Int.* 2002; 90: 893-897.
PubMed: <https://www.ncbi.nlm.nih.gov/pubmed/12460352>
4. Martinez-Salamanca JI, Mueller A, Moncada I, et al. Penile prosthesis surgery in patients with corporal fibrosis: a state of the art review. *J Sex Med.* 2011; 8: 1880-1889.
PubMed: <https://www.ncbi.nlm.nih.gov/pubmed/21492405>
5. Wilson SK, Zumbo J, Henry GD, Delk JR, Cleves MA. et al. Infection reduction using antibiotic-coated inflatable penile prosthesis. *Urology.* 2007; 70: 337-340.
PubMed: <https://www.ncbi.nlm.nih.gov/pubmed/17826502>
6. Ralph DJ, Garaffa G, Muneer A, Freeman A, Rees R, et al. The immediate insertion of a penile prosthesis for acute ischaemic priapism. *Eur Urol.* 2009; 56: 1033-1038.
PubMed: <https://www.ncbi.nlm.nih.gov/pubmed/18930579>