

Case Report

Other Applications of Amniotic Membranes: Case Series

Linda Guerrero^{1,2*}, Malagon A¹, Forero C¹ and Salguero G¹

¹Tissue Bank, Instituto Distrital de Ciencia Biología e Innovación en Salud, IDCBIS

²Plastic and Reconstructive Surgeon, Laminar Tissue Bank Director, District Institute of Science Biotechnology and Innovation in Health Tissue Bank, Burn Foundation, Scientific Director, Bogotá, Colombia

Abstract

The amniotic membrane, used for over a century, is a widely recognized therapeutic tool in regenerative medicine and reconstructive surgery. Its primary indication is in the treatment of deep partial-thickness burns, where it facilitates epithelialization by providing an optimal environment for tissue regeneration. However, its versatility allows its use in various clinical scenarios, particularly in wounds or trauma where immediate closure is not possible, either due to the patient's condition or the characteristics of the wound itself. Its most notable benefits include the prevention of necrosis due to desiccation, minimizing the loss of essential proteins, fluids, and electrolytes, reducing the risk of infection by acting as a physical barrier and alleviating pain by covering and stabilizing the wound.

Additionally, its ability to act as a temporary biological cover offers a valuable solution in complex cases, improving both the prognosis and the patient's management.

A case series is presented demonstrating various applications of the amniotic membrane.

Introduction

Amniotic membranes have been used in clinical practice for over a century. In 1979, Trelford conducted a significant review of all literature published up to that point, documenting their use as grafts for creating artificial vaginas, "amnioplastin", to prevent meningeal and cerebral adhesions, and their application in trauma and burn wounds¹. The chorion and amnion layers of the amniotic membrane differ notably in appearance and structure: amnion: This is the thinner and translucent layer. It is smooth, elastic, and delicate, which makes it ideal for applications requiring close adherence to the wound or tissue surface. Chorion: This is the thicker and opaque layer. It has a more robust structure, providing greater mechanical support when used in therapeutic settings [1-6].

The contrast between these layers—the amnion's fine and transparent characteristics versus the chorion's denser and less transparent nature—highlights their complementary roles, allowing for tailored applications based on the clinical requirements (Figure 1 A-D).

Each exhibits different behaviors: the amniotic layer facilitates epithelialization, adheres less, and is less immunogenic, while the chorionic layer adheres more firmly or "integrates," promoting the formation of granulation tissue. Later studies showed that the reduction in infection

among burn patients was not due to bactericidal properties but rather to the temporary wound closure provided by the membrane [2,3].

Applied to a wide variety of clinical scenarios including burns, chronic ulcers, dural defects, intra-abdominal adhesions, peritoneal reconstruction, genital reconstruction, hip arthroplasty, tendon repair, nerve repair, microvascular

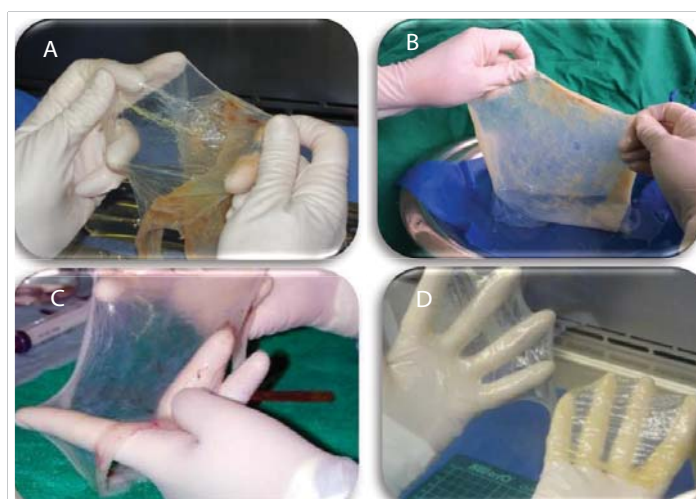


Figure 1: A: separation of the two layers of the amniotic membrane, amnion, and chorion B: chorion appearance: thicker and opaque, C: amnion: thinner, transparent, smooth, and elastic. D: note the differences between the two amniotic layers: the amnion, is thinner, and the chorion thicker.

More Information

***Address for correspondence:** Linda Guerrero, MD, Plastic and Reconstructive Surgeon, Laminar Tissue Bank Director, District Institute of Science Biotechnology and Innovation in Health Tissue Bank, Burn Foundation, Scientific Director, Bogotá, Colombia, Email: direccion@fundaciondelquemado.org

Submitted: December 02, 2024

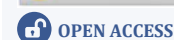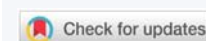
Approved: December 20, 2024

Published: December 23, 2024

How to cite this article: Guerrero L, Malagon A, Forero C, Salguero G. Other Applications of Amniotic Membranes: Case Series. Arch Case Rep. 2024; 8(3): 159-162. Available from: <https://dx.doi.org/10.29328/journal.acr.1001117>

Copyright license: © 2024 Guerrero L, et al. This is an open access article distributed under the Creative Commons Attribution License, which permits unrestricted use, distribution, and reproduction in any medium, provided the original work is properly cited.

Keywords: Amnion; Chorion; Temporary cover; Tissue bank



reconstruction, corneal repair, intra-oral reconstruction and reconstruction of the nasal lining and tympanic membrane [4-6].

With the establishment of skin and amnion banks, that provide safe and high-quality tissues, amniotic membranes have regained importance.

In the Instituto Distrital de Ciencia y Biotecnología en Salud (BT-IDCBIS in Spanish) in Bogotá Colombia, we process and preserve tissues with glycerol 85%. Glycerol dehydrates tissues, protecting cellular integrity and preserving their characteristics and properties.

As the director of the laminar tissue bank at the BT-IDCBIS, I have applied or asses other plastic surgeons in the use of amniotic membranes.

Case series

A series of cases involving the application of amniotic membranes in various pathologies were reviewed.

Case 1

A 12-year-old male patient involved in a car accident required delayed definitive closure of the distal leg due to the risk of compartment syndrome. The membrane was applied, and upon removal, the tissue exhibited excellent vitality, allowing for definitive closure (Figure 2 A-D).

Case 2

A 45-year-old male patient developed Fournier's gangrene necrotizing fasciitis following a hemorrhoidectomy. Forty-eight hours post-debridement, tissue necrosis due to desiccation was observed. The membrane was applied twice, followed by a partial-thickness skin autograft, achieving 100% integration. The membrane isolated the wound from contamination in a complex area and prepared the bed with healthy granulation tissue, supported by 100% take graft (Figure 3 A-E).

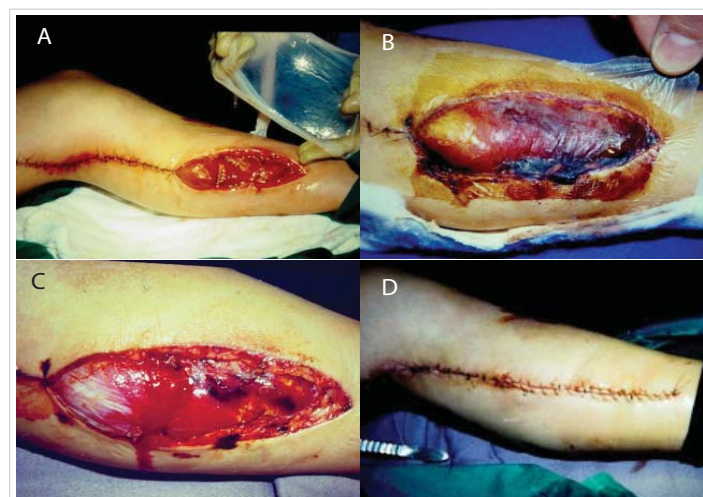

Figure 2: A: A 12-year-old male patient involved in a car accident: amnion temporary cover. B: amnion adherence to wound. C: appearance of the wound after removal of the amnion; note the vitality of the tissue D: definitive closure without any complication.

Case 3

A 37-year-old patient with toxic epidermal necrolysis as a reaction to acyclovir had 70% body surface involvement. Amniotic membranes were applied, promoting epithelialization. However, in the gluteal region, temporary integration of the membranes was not achieved, and this area was managed with different silver-based dressings (Figure 4 A-E).

Case 4

An 11-year-old female patient within situ melanoma underwent Mohs surgery. The wound was temporarily covered with amnion twice before definitive coverage. Importantly, the patient experienced no pain, avoided contamination, and preserved vital tissue for the flap reconstruction (Figure 5 A-D).

Case 5

A 92-year-old female patient with full-thickness burn due to acetic acid on the right knee and leg; was temporarily covered with amnion after scar debridement on two occasions. Promote granulating tissue and border epithelization. Due to her age and comorbidities, the family did not want autograft (Figure 6 A-D).

Discussion

All cases demonstrated the benefits of amniotic membrane application; amnion takes or adheres within the first

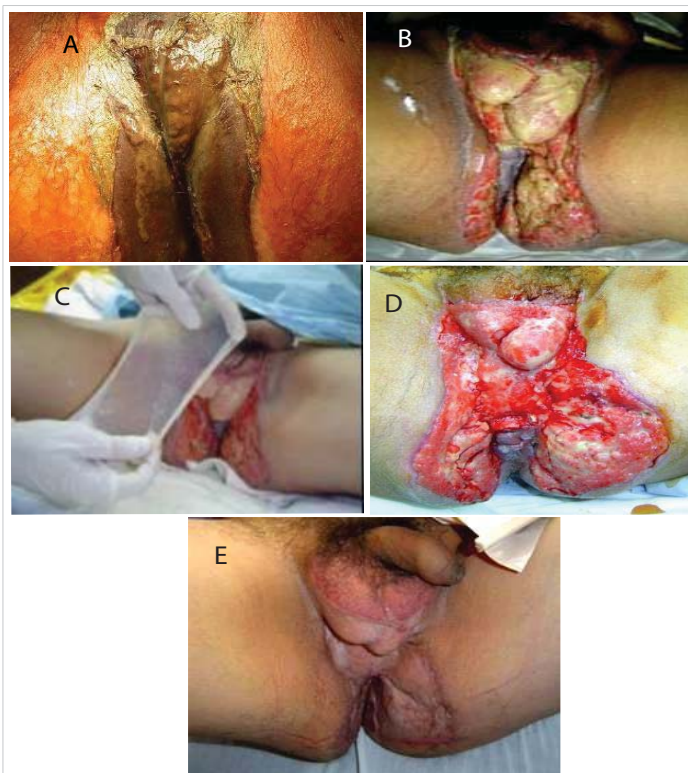


Figure 3: A: 45-year-old male patient developed Fournier's gangrene B: Forty-eight hours post-debridement, tissue necrosis due to desiccation was observed C: two amnion applications. D: granulating tissue after amnion removal E: autograft take 100%.

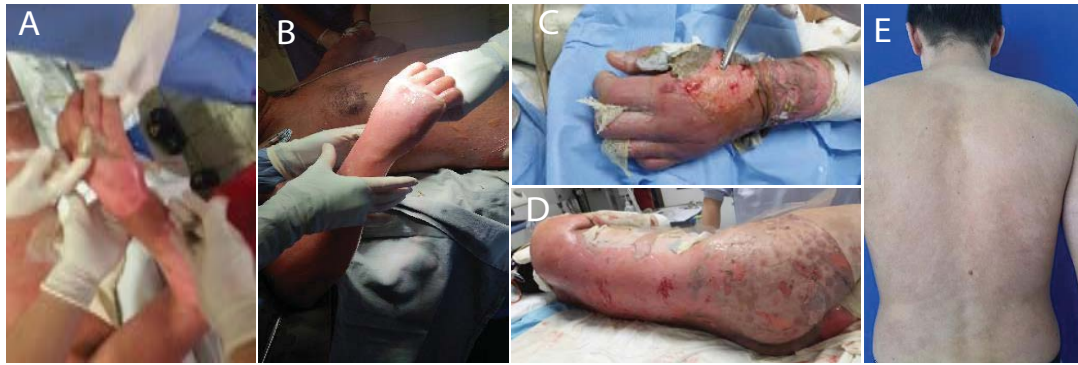

Figure 4: A 37-year-old male patient with toxic epidermal necrolysis, 70% body surface involvement B: application of amnion on the hand. C. amnion aspect after first wound dressing change. D: amnion on the back. E: complete epithelization.

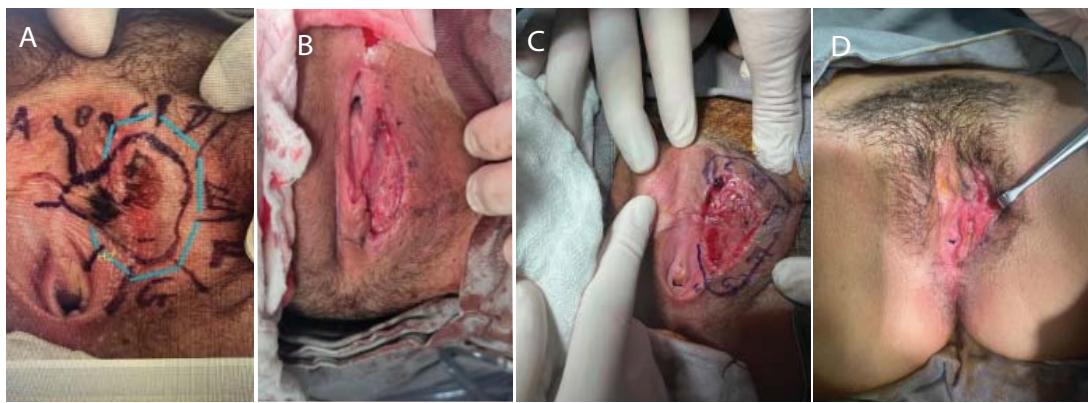

Figure 5: A: Mohs surgery in an 11-year-old female patient within situ melanoma B: temporary cover for eight days. C: margin expansion due to edge commitment and new amnion application D: skin edges free from ca and ready for definitive closure with local flap. No pain, no infection.

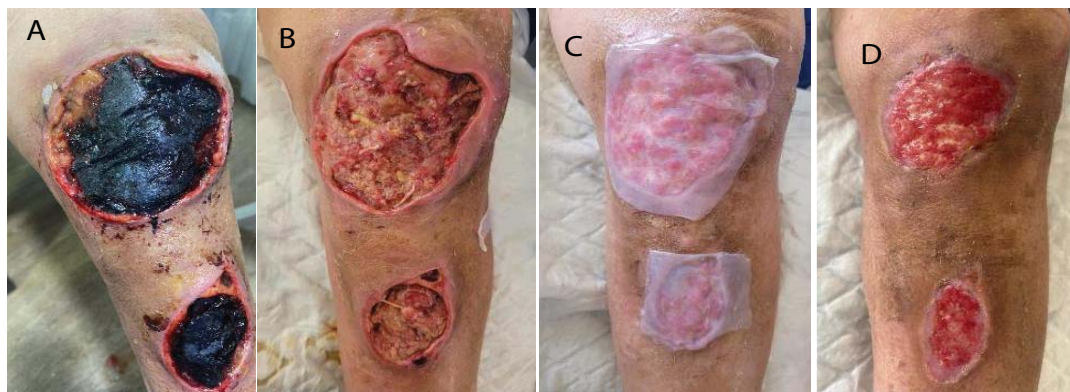


Figure 6: A: A 92-year-old female patient with full-thickness burn due to acetic acid on the right knee and leg. B: the appearance of the wound after debridement. C: amnion application. D: note the formation of granulation tissue, epithelialization at the edges, and shrinkage of the wounds by contraction.

24–48 hours. If placed with the amniotic side facing the wound, minimal fixation is observed after 72 hours, and neovascularization does not occur. Preserved tissue vitality for differed wound closure; the membranes enhanced granulation tissue formation and supported 100% take graft in complex areas. Amnion alleviated pain, prevented wound desiccation, and promoted early epithelialization in a critical patient with toxic epidermal necrolysis. Their ability to adhere to the wound bed contributes to suppressing bacterial

proliferation and aids in eliminating present bacteria. They also require fewer dressing changes.

Conclusion

Amniotic membranes remain a valuable resource, not only for managing partial thickness burns but also for treating other wounds caused by various pathologies or trauma. They are safe, high-quality, and cost-effective.



Ethical considerations

All patients provided informed consent for the application of amniotic membranes and were granted authorization for the publication of their cases in scientific journals or presentations at scientific events.

References

1. Trelford JD, Trelford-Sauder M. The amnion in surgery, past and present. *Am J Obstet Gynecol*. 1979;134(7):833-845. Available from: [https://doi.org/10.1016/0002-9378\(79\)90957-8](https://doi.org/10.1016/0002-9378(79)90957-8)
2. Robson MC, Krizek TJ. The effect of human amniotic membranes on the bacterial population of infected rat burns. *Ann Surg*. 1973;177:144-149. Available from: <https://doi.org/10.1097/00000658-197302000-00003>
3. Robson MC, Krizek TJ. Amniotic membranes as a temporary wound dressing. *Surg Gynecol Obstet*. 1973;136:904-906. Available from: <https://pubmed.ncbi.nlm.nih.gov/4703471/>
4. Fairbairn NG, Randolph MA, Redmond RW. The clinical applications of human amnion in plastic surgery. *J Plast Reconstr Aesthet Surg*. 2014;67(5):662-675. Available from: <https://doi.org/10.1016/j.bjps.2014.01.031>
5. Branski LK, Herndon DN, Celis MM, Norbury WB, Masters OE, Jeschke MG. Amnion in the treatment of pediatric partial-thickness facial burns. *Burns*. 2008;34(3):393-399. Available from: <https://doi.org/10.1016/j.burns.2007.06.007>
6. Vloemans van der Wal H, Liebrechts J, Middelkoop E. Optimal treatment of partial thickness burns in children: A systematic review. *Burns*. 2014;40(2):177-190. Available from: <https://doi.org/10.1016/j.burns.2013.09.016>